Serviço de Imagem Médica
Centro Hospitalar e Universitário de Coimbra
Faculdade de Medicina de Coimbra

APLICAÇÕES EXTRA-HEPÁTICAS DA ECOGRAFIA CONTRASTADA

Henrique Donato, Francisco Pereira da Silva, Pedro Belo Oliveira,
Pedro Belo Soares, Filipe Caseiro Alves

Sumário

- Introdução e objectivos
- Materiais e métodos
- Aplicações extra-hepáticas
- Conclusões

Introdução

- Ecografia contrastada (CEUS)

- Microbolhas
  - Exclusivamente intravascular
  - Exalado nos pulmões ao fim de 5min

Contra-indicações

- Patologia cardíaca grave
- Gravidez
- Aleitamento

Introdução

Vantagens CEUS

- Ausência de radiação ionizante
- Execução em tempo real
- Ausência de nefrotoxicidade
- Baixa incidência de efeitos secundários

Limitações CEUS

- Reflectem as limitações da ecografia convencional

Introdução

- Bem estabelecida na avaliação lesões hepáticas focais
- Pode estender-se a outros órgãos, tirando partido das vantagens

➢ Objectivos

Materiais e Métodos

- Revisão de estudos CEUS extra-hepáticos
- Imagens do Serviço de Imagem Médica, CHUC

Aplicações Extra-hepáticas

Baço

Lesão benigna: Hemangioma

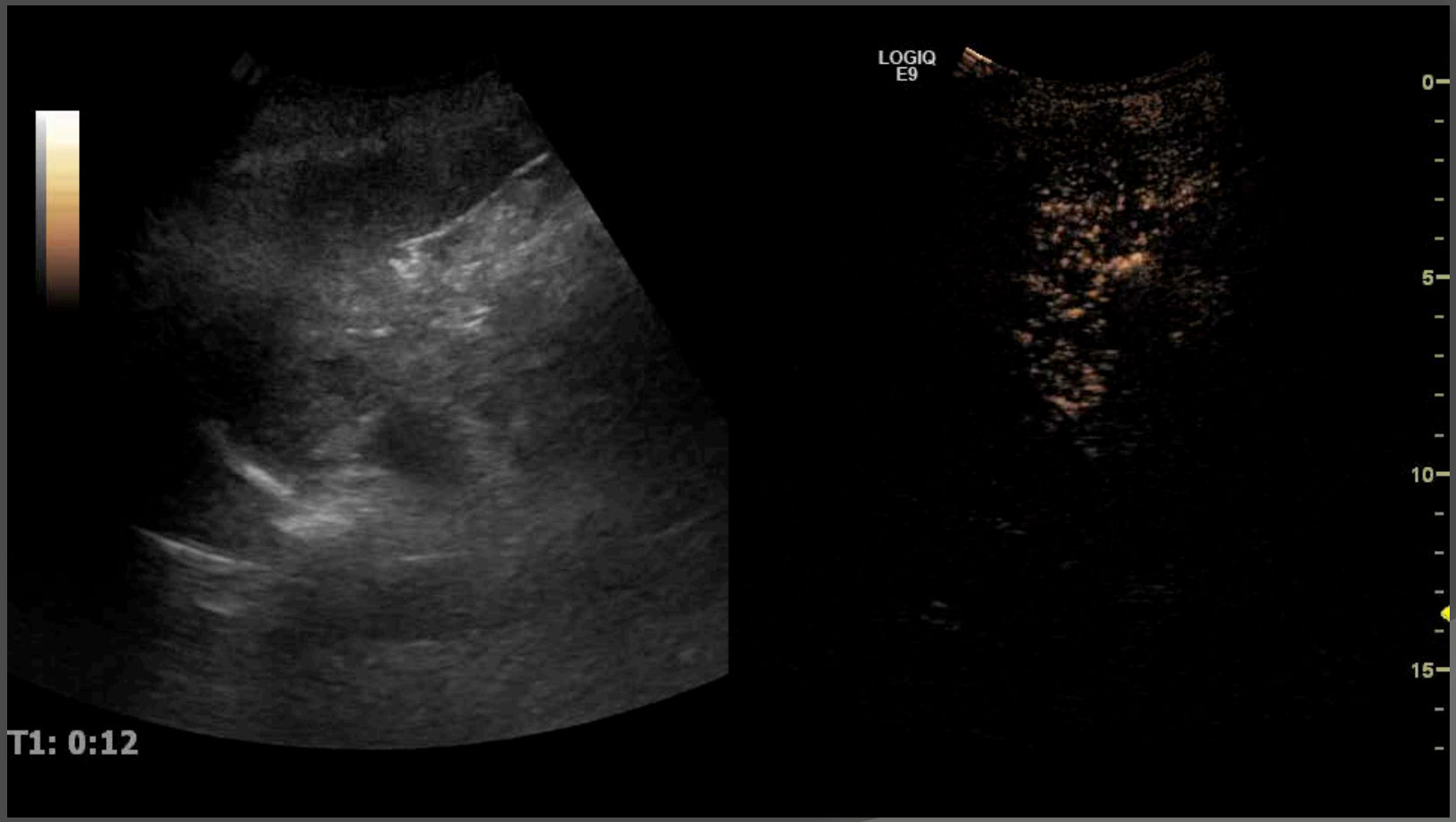

Baço

Lesão benigna: Hemangioma

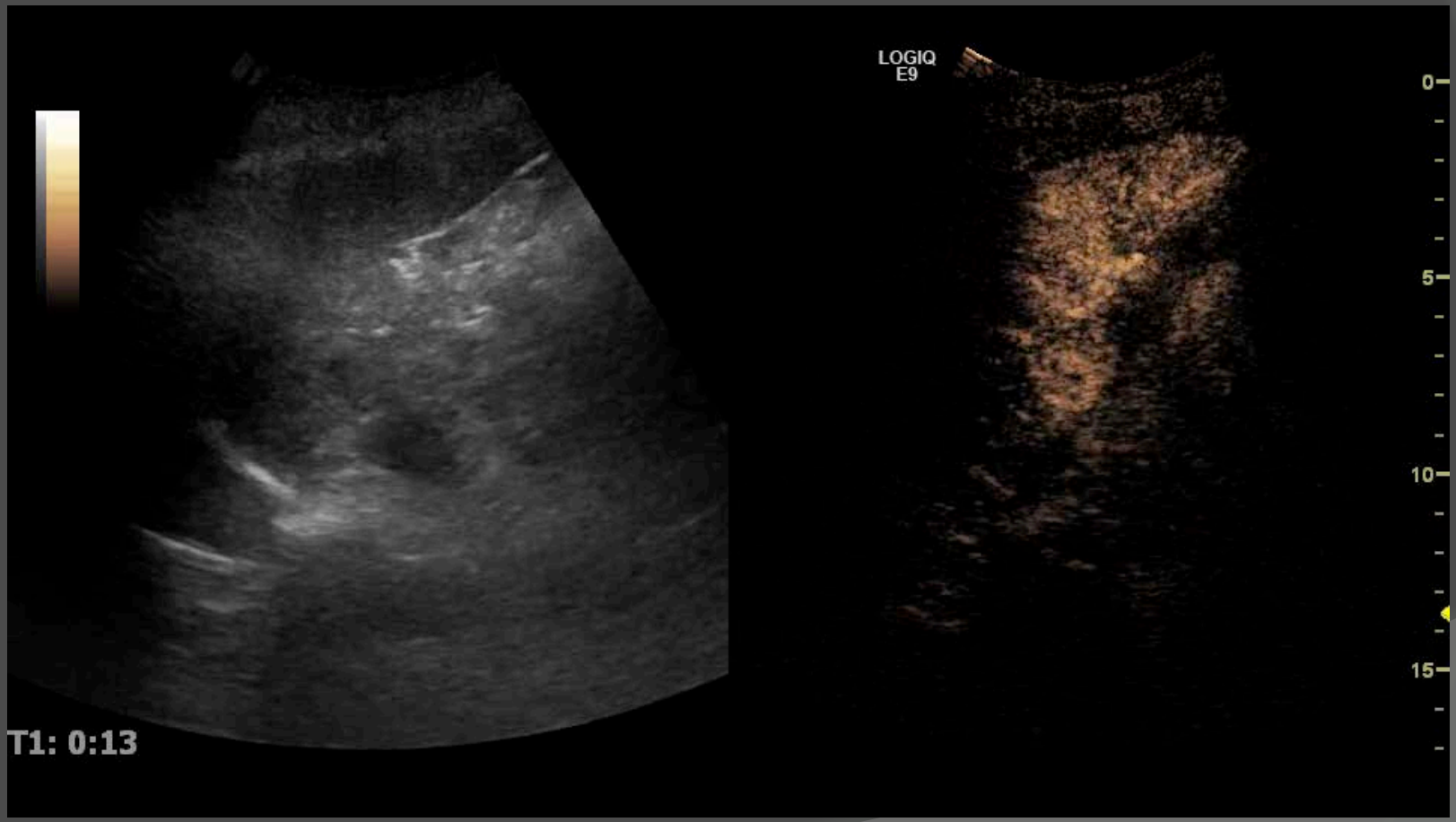

Baço

Lesão benigna: Hemangioma

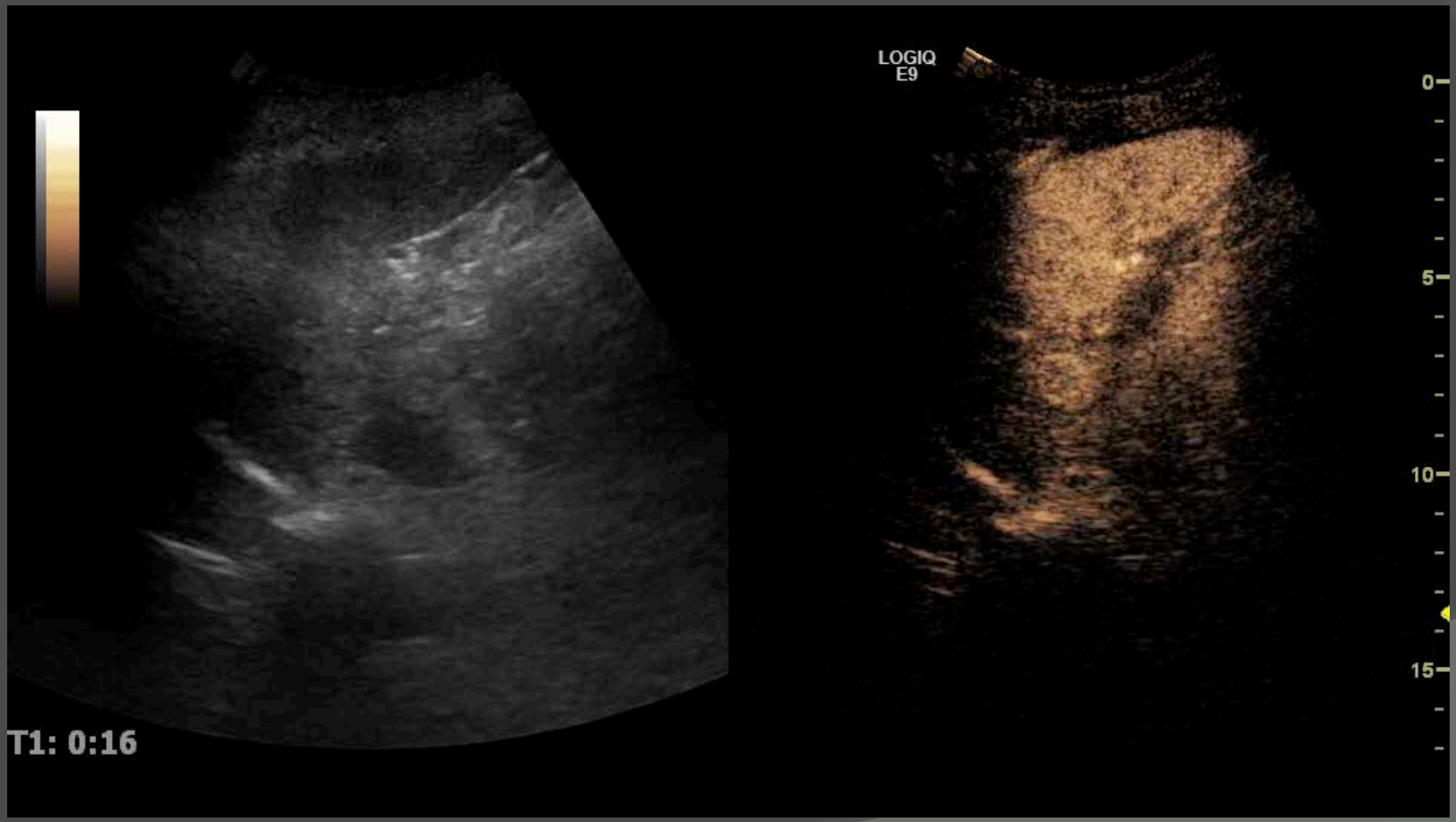

Baço

Lesão benigna: Hemangioma

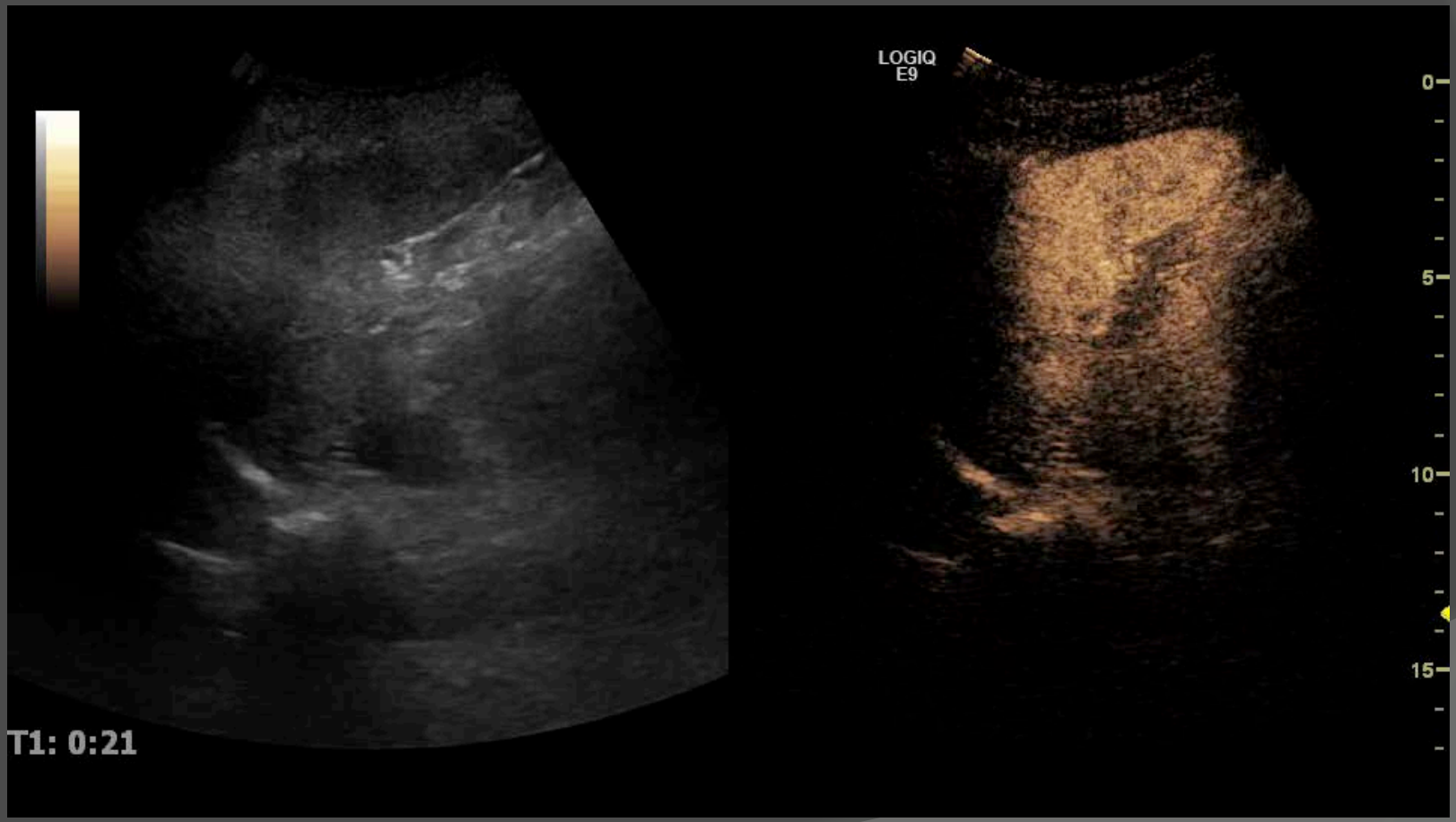

Baço

Lesão benigna: Hemangioma

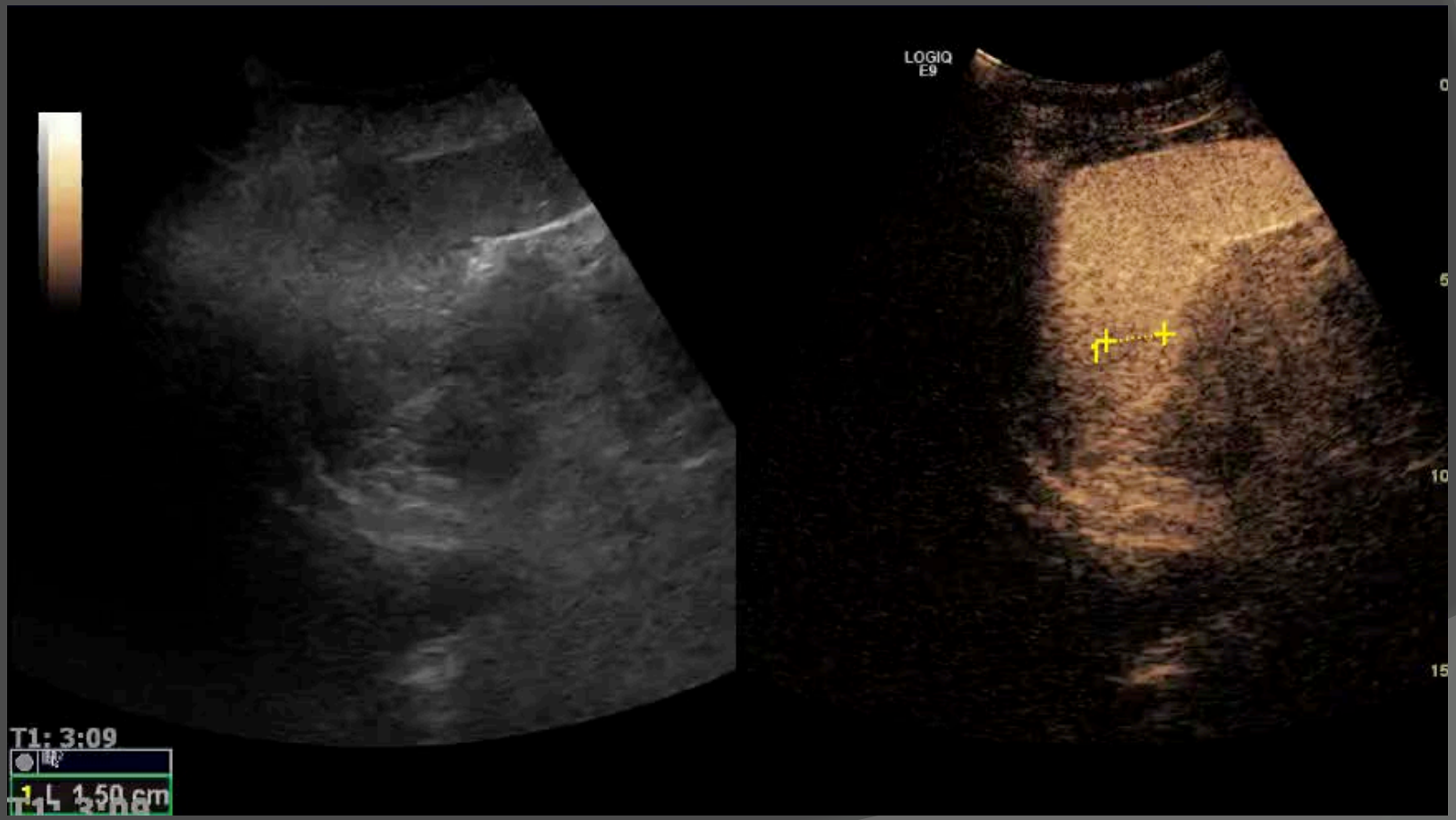

Baço

Lesão maligna: Infiltração linfomatosa

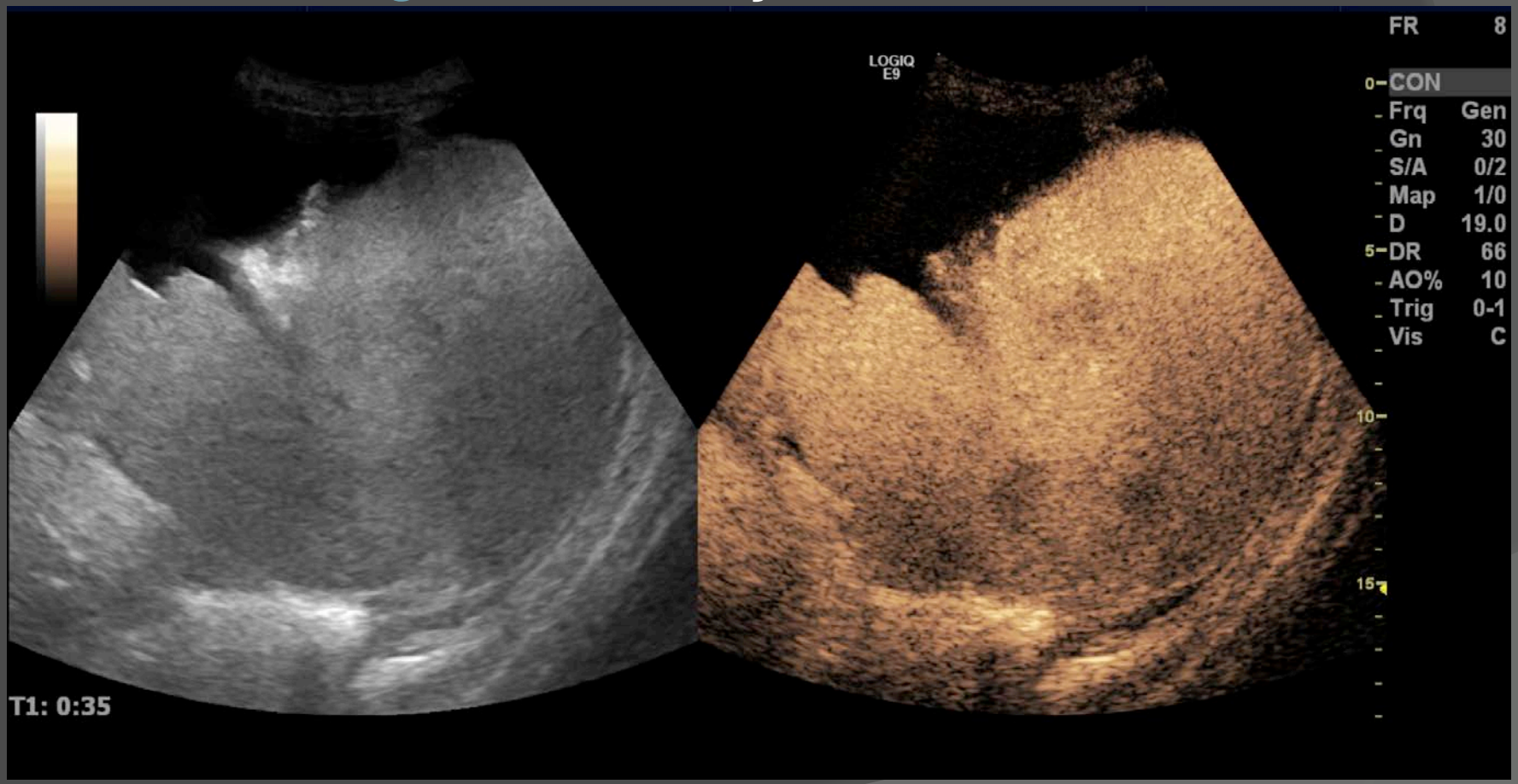

Baço

Lesão maligna: Infiltração linfomatosa

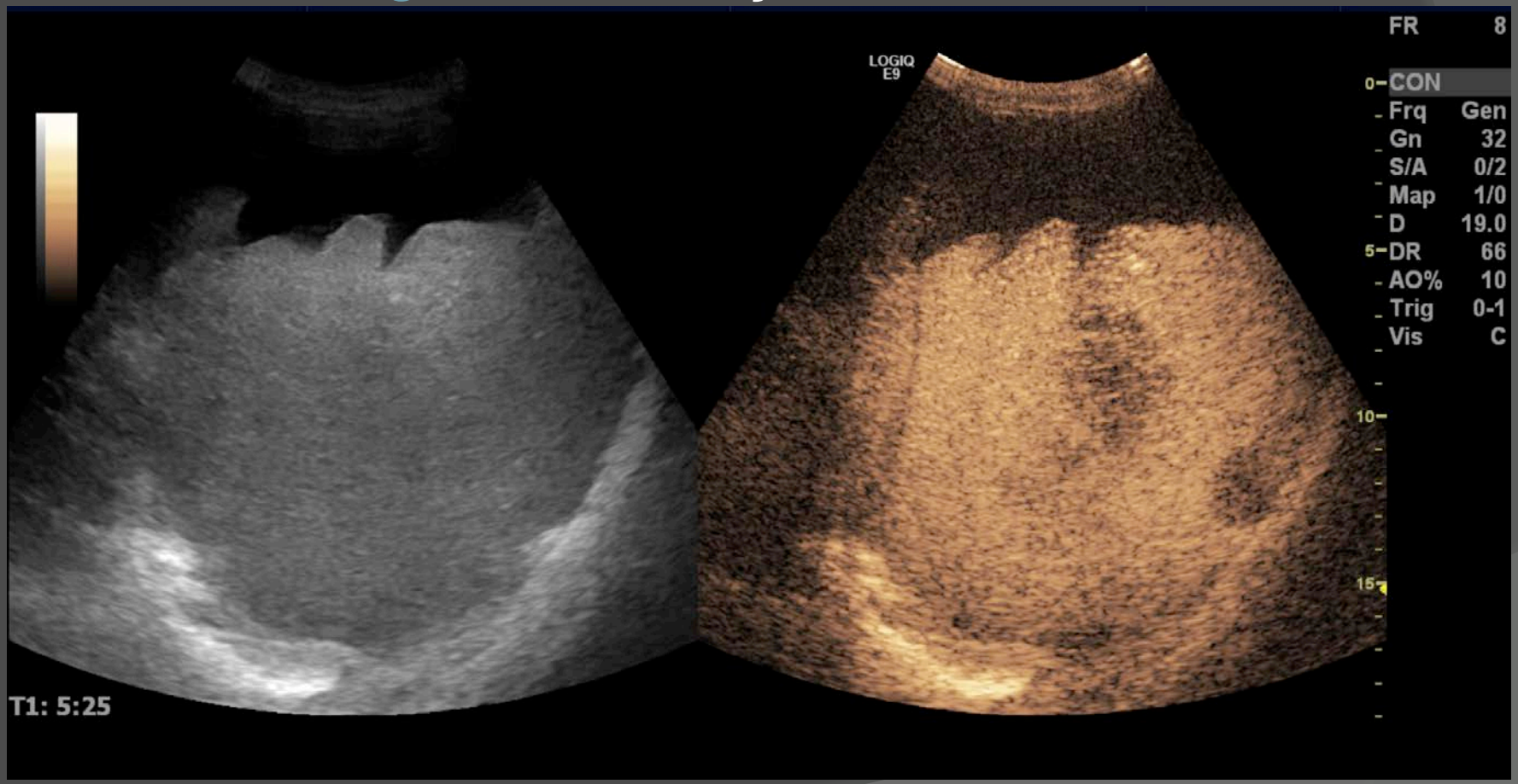

Baço

Trauma: Laceração

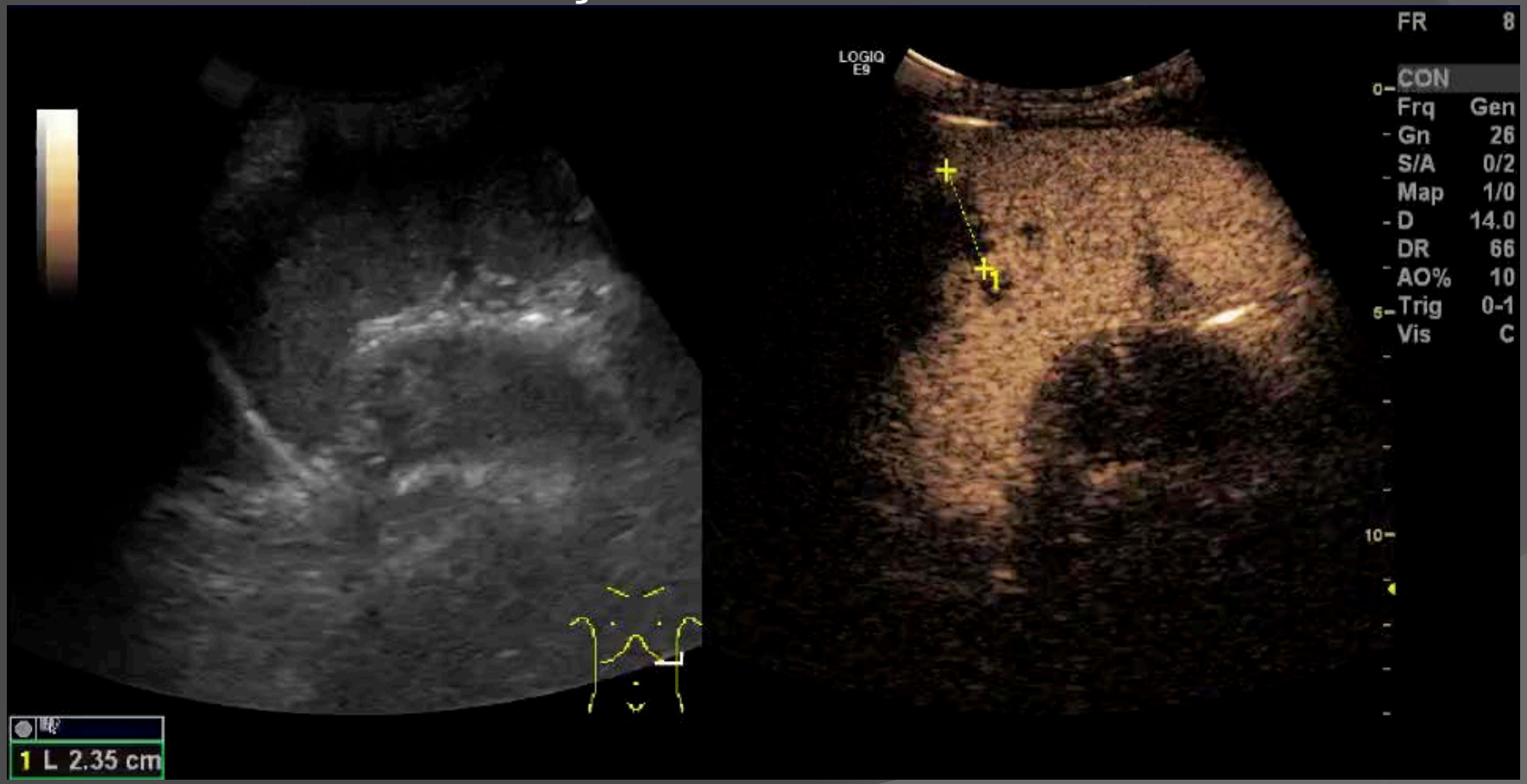

Baço

Outras aplicações:

- Esplenose
- Baço acessório
- Enfarte

Pâncreas

- Lesão quística

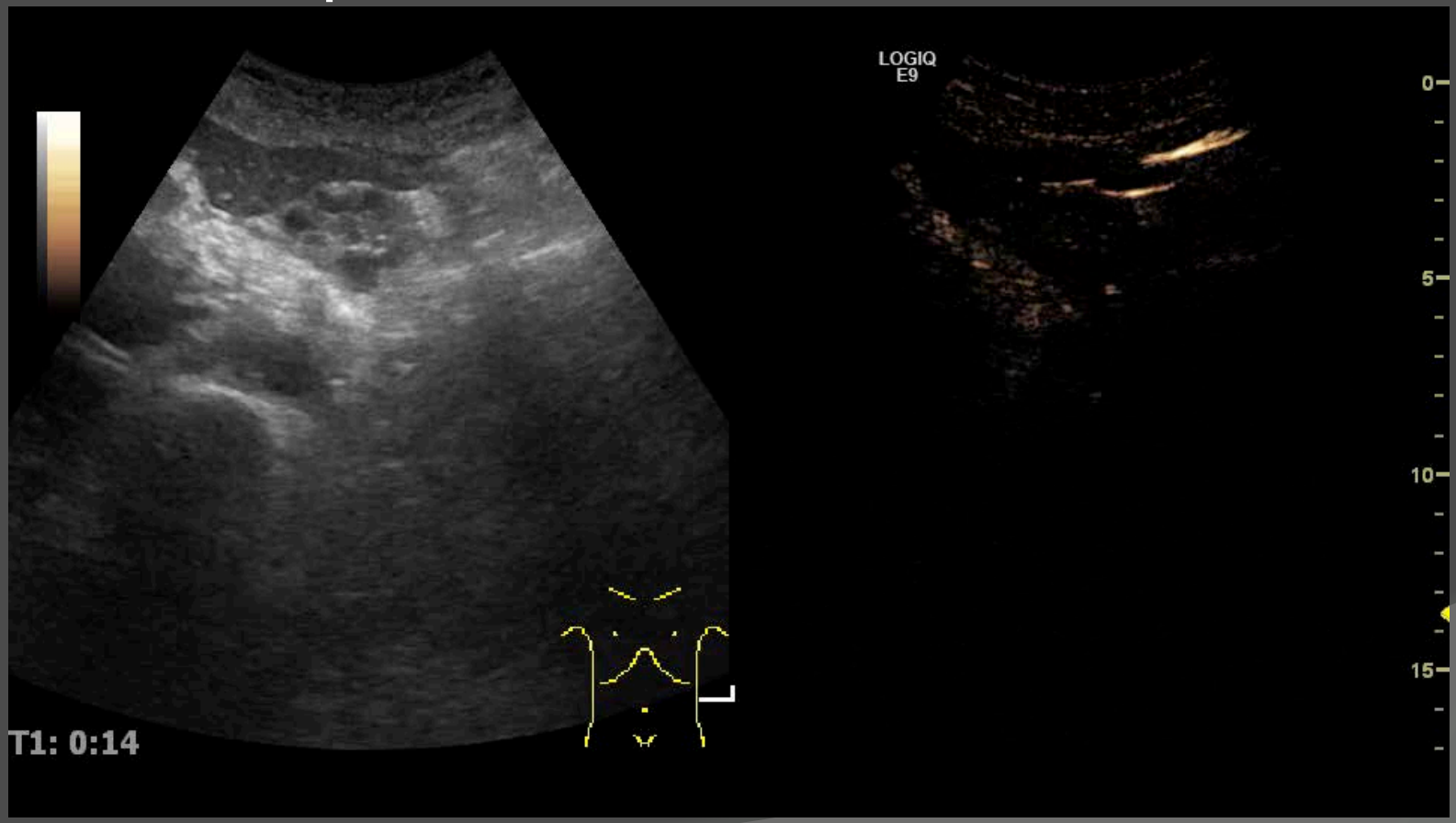

Pâncreas

- Lesão quística

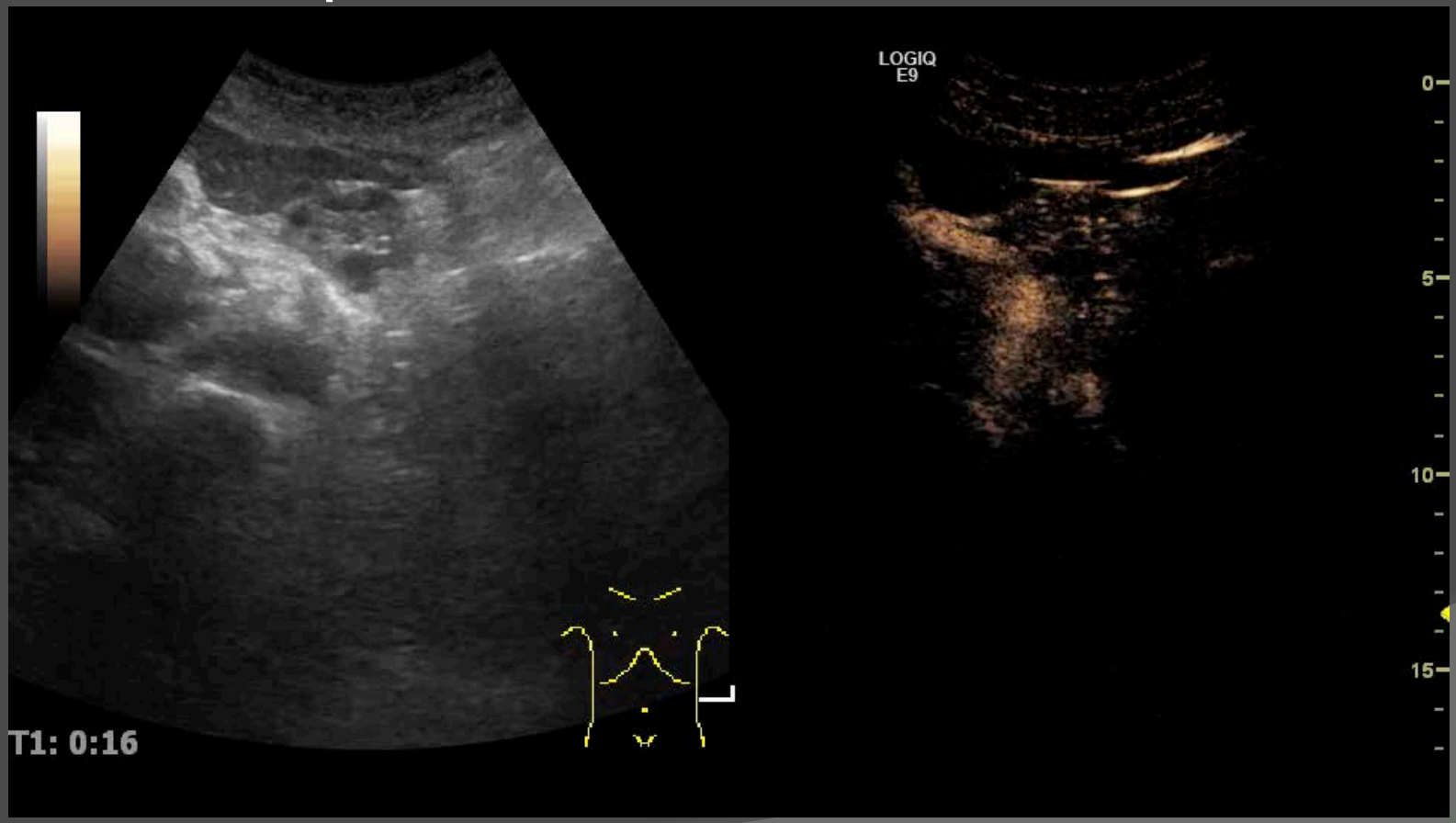

Pâncreas

- Lesão quística

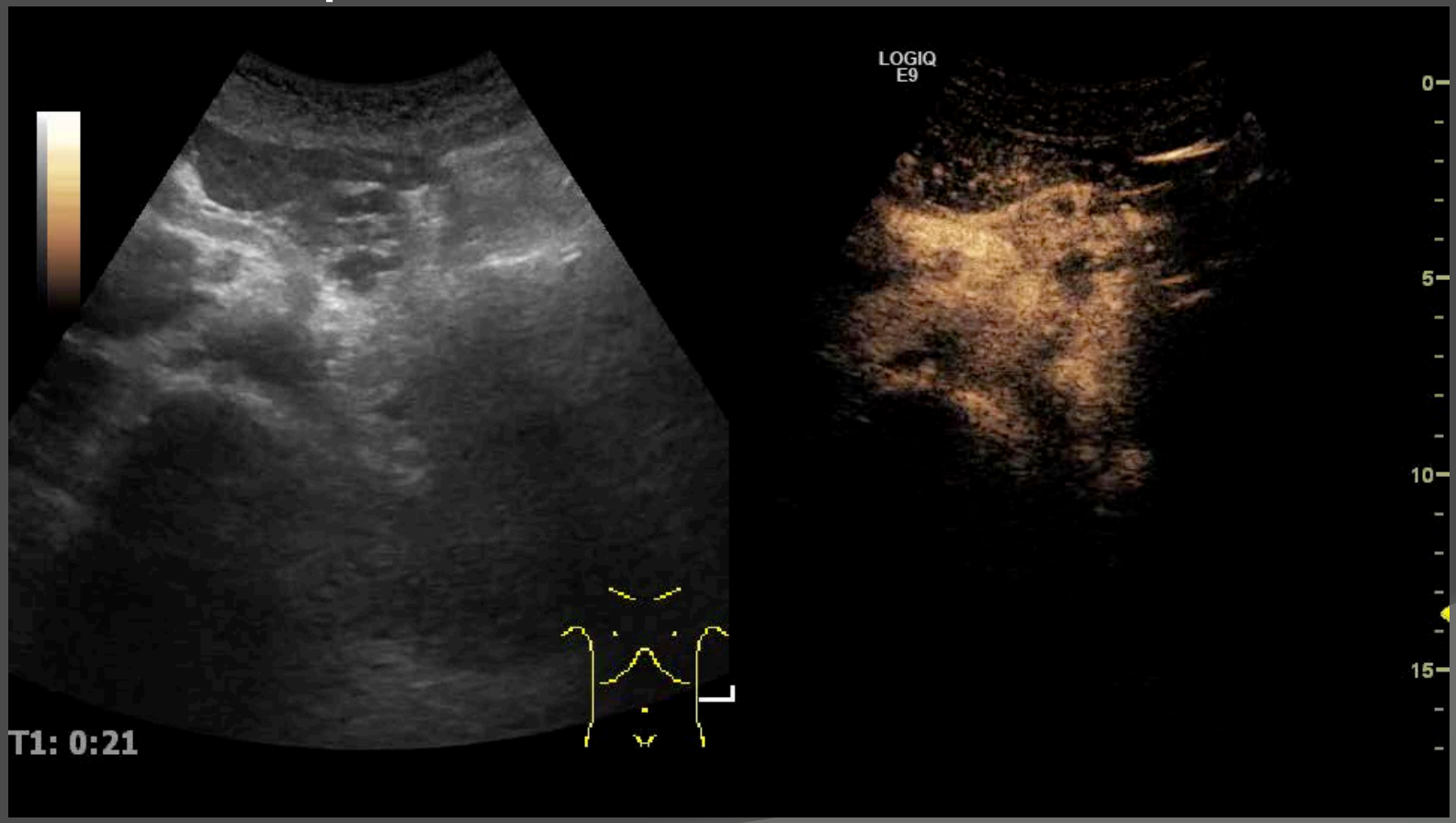

Pâncreas

- Lesão quística

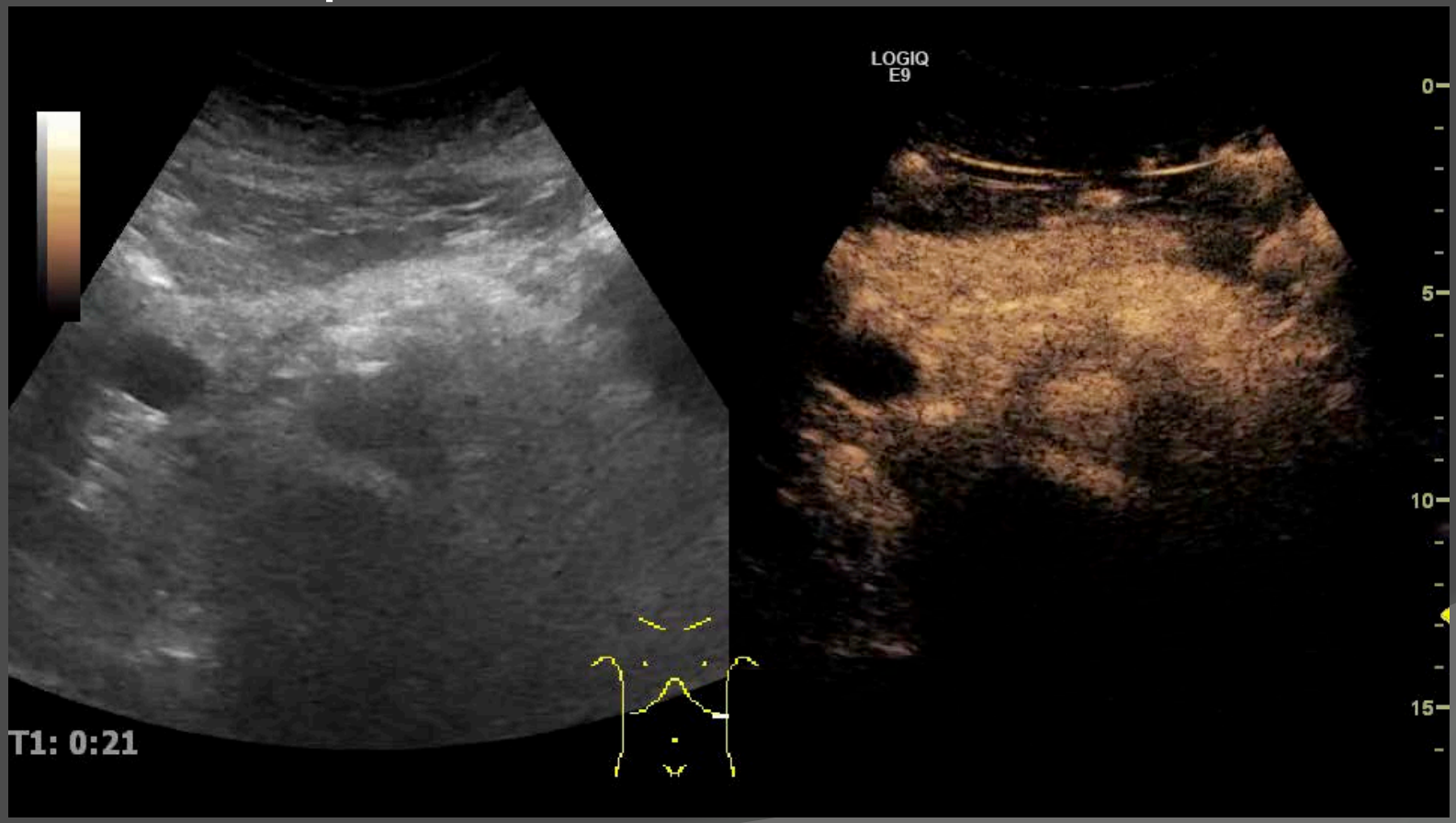

Pâncreas

Outras aplicações:

- Lesões sólidas
- Pancreatite aguda: áreas de necrose

Rim

- Quisto complexo sem realce

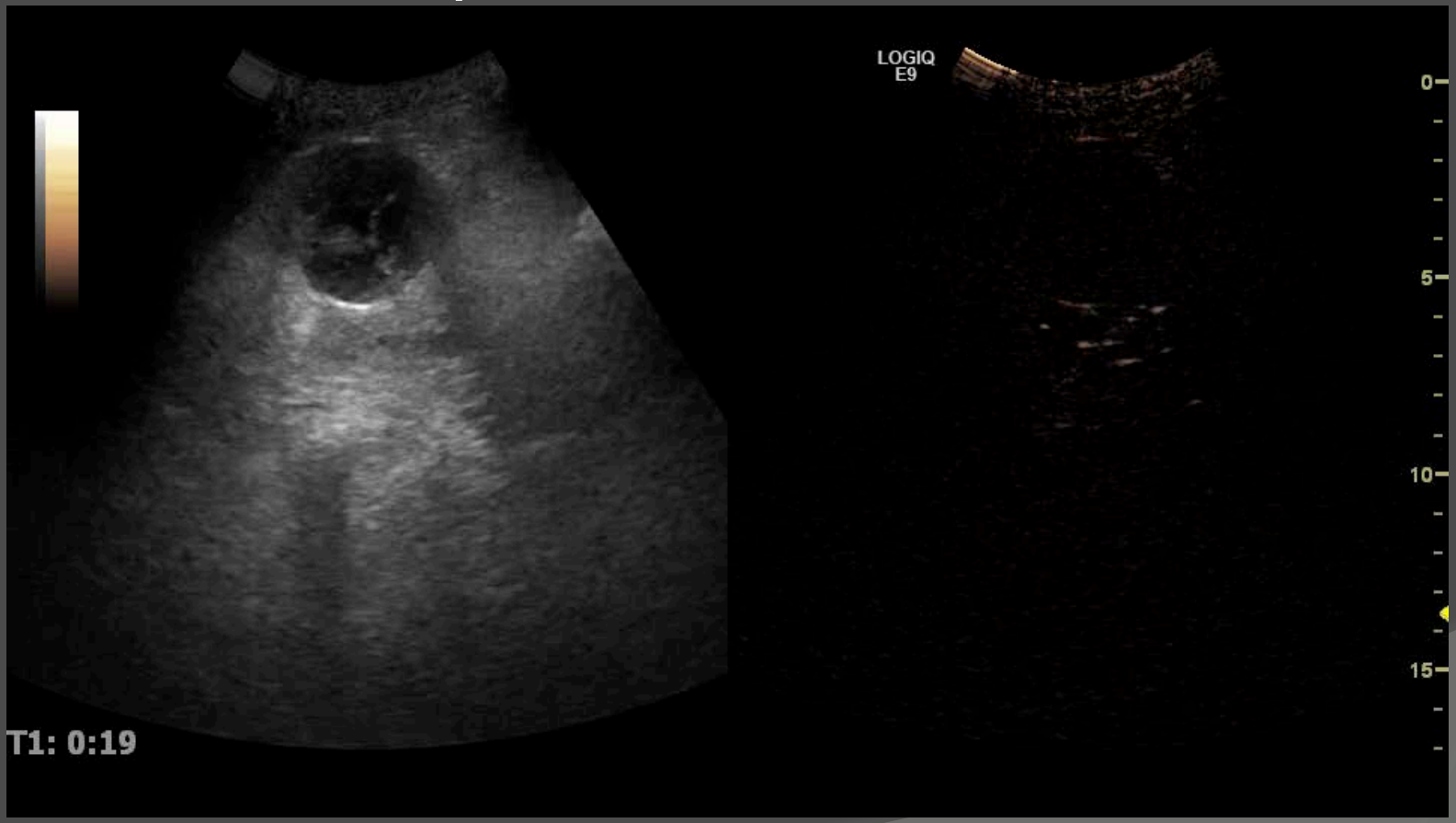

Rim

- Quisto complexo sem realce

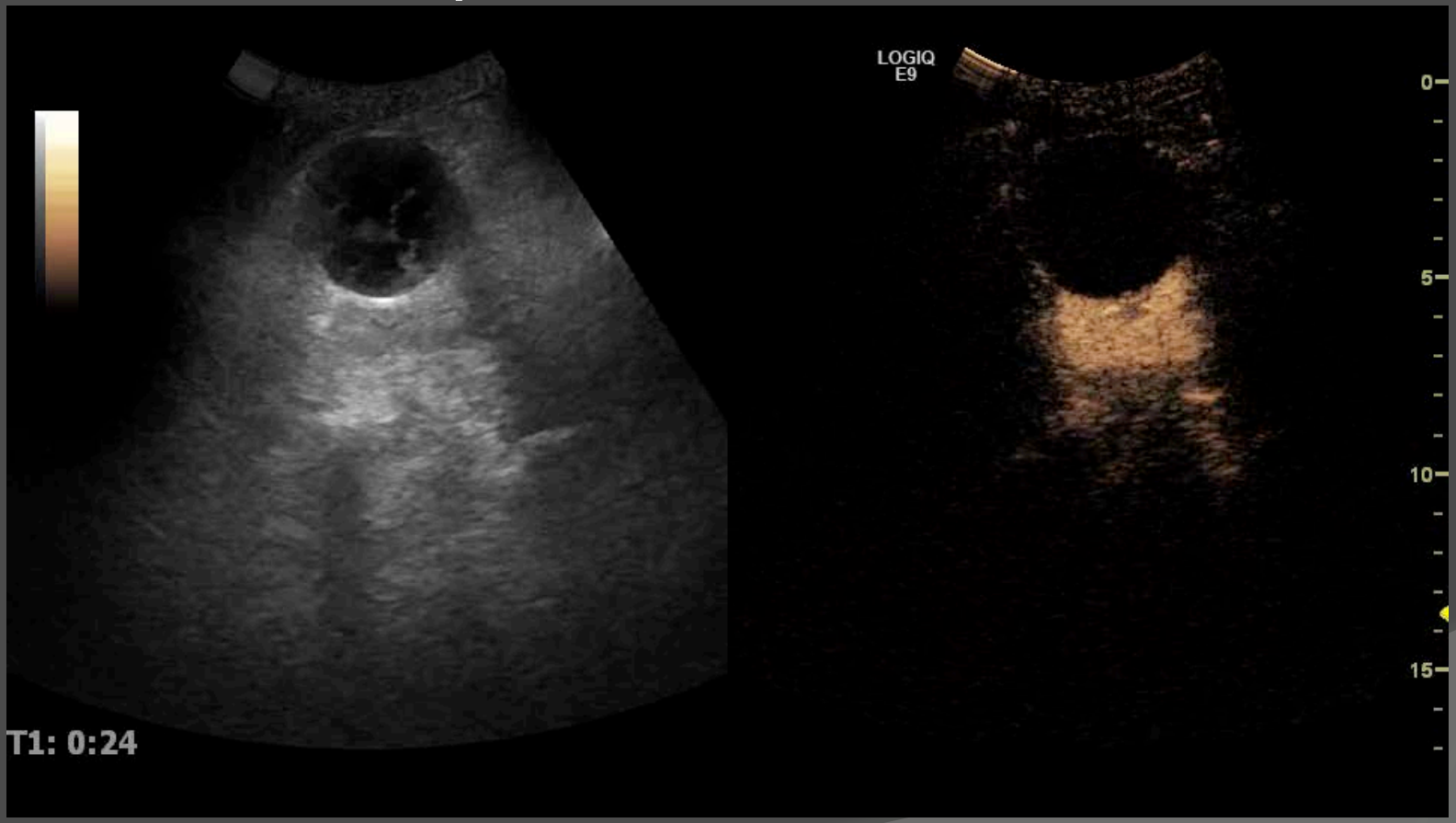

Rim

- Quisto complexo sem realce

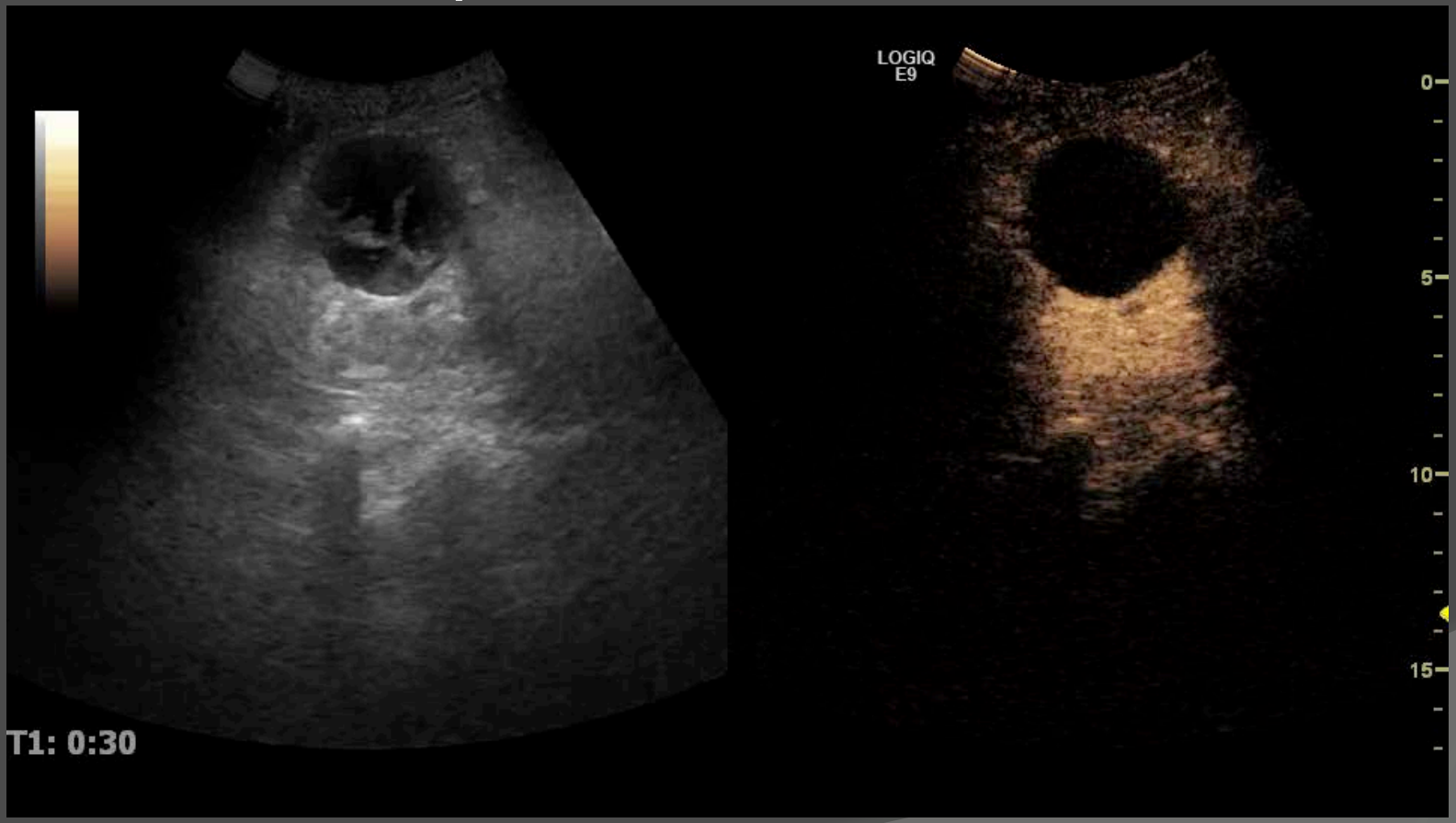

Rim

- Quisto complexo com realce

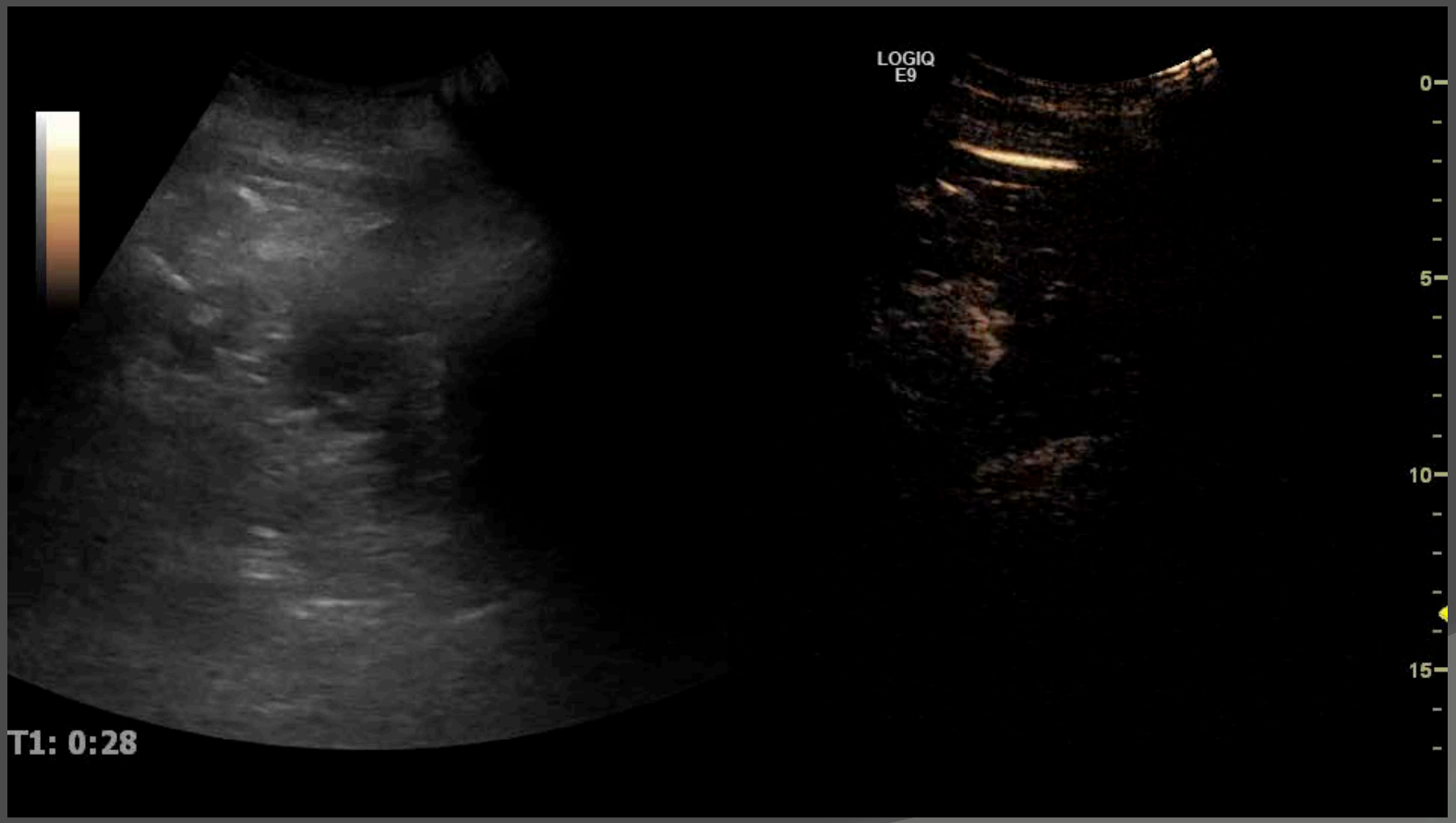

Rim

- Quisto complexo com realce

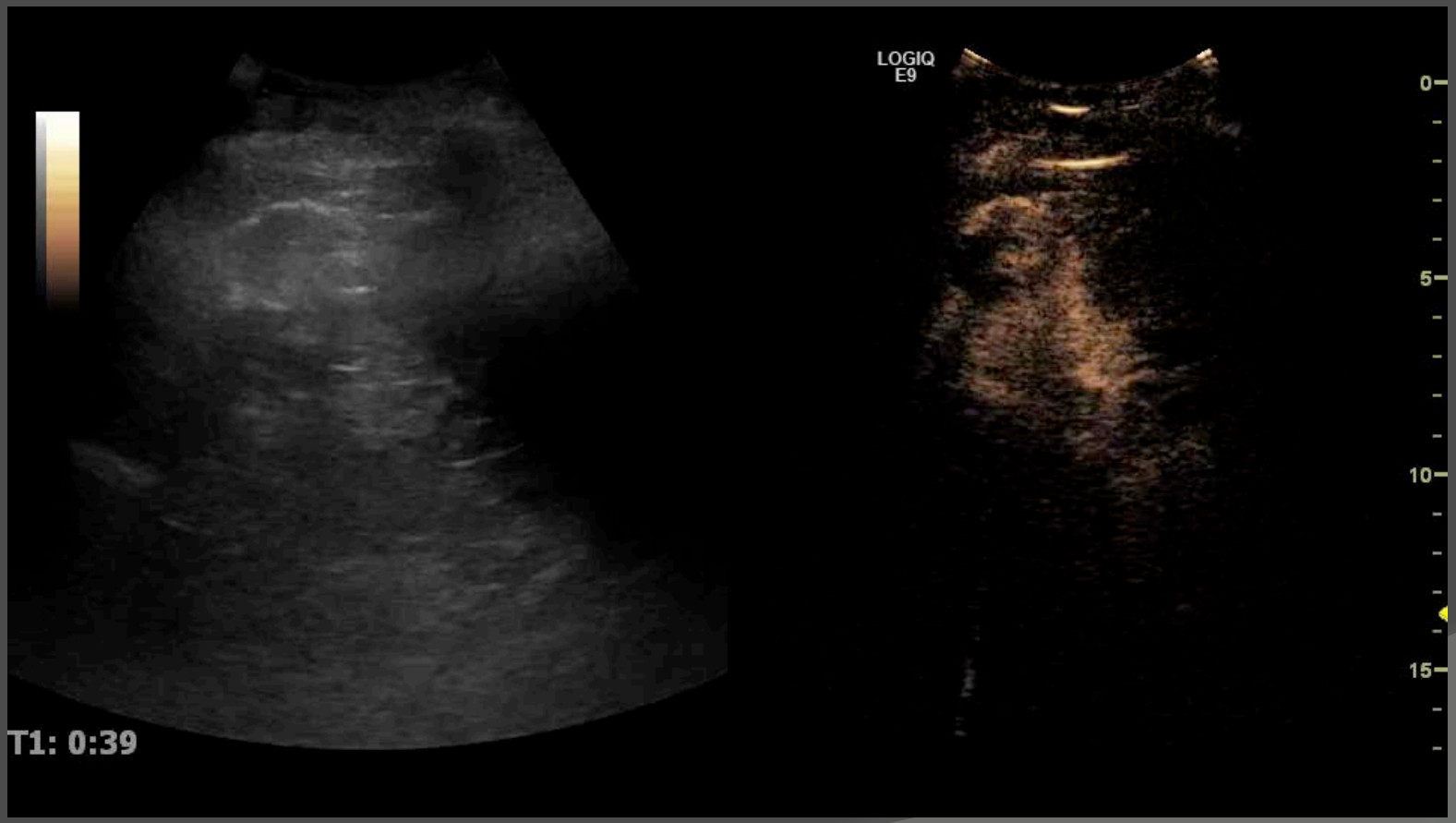

Rim

- Enxerto renal: Quisto complexo

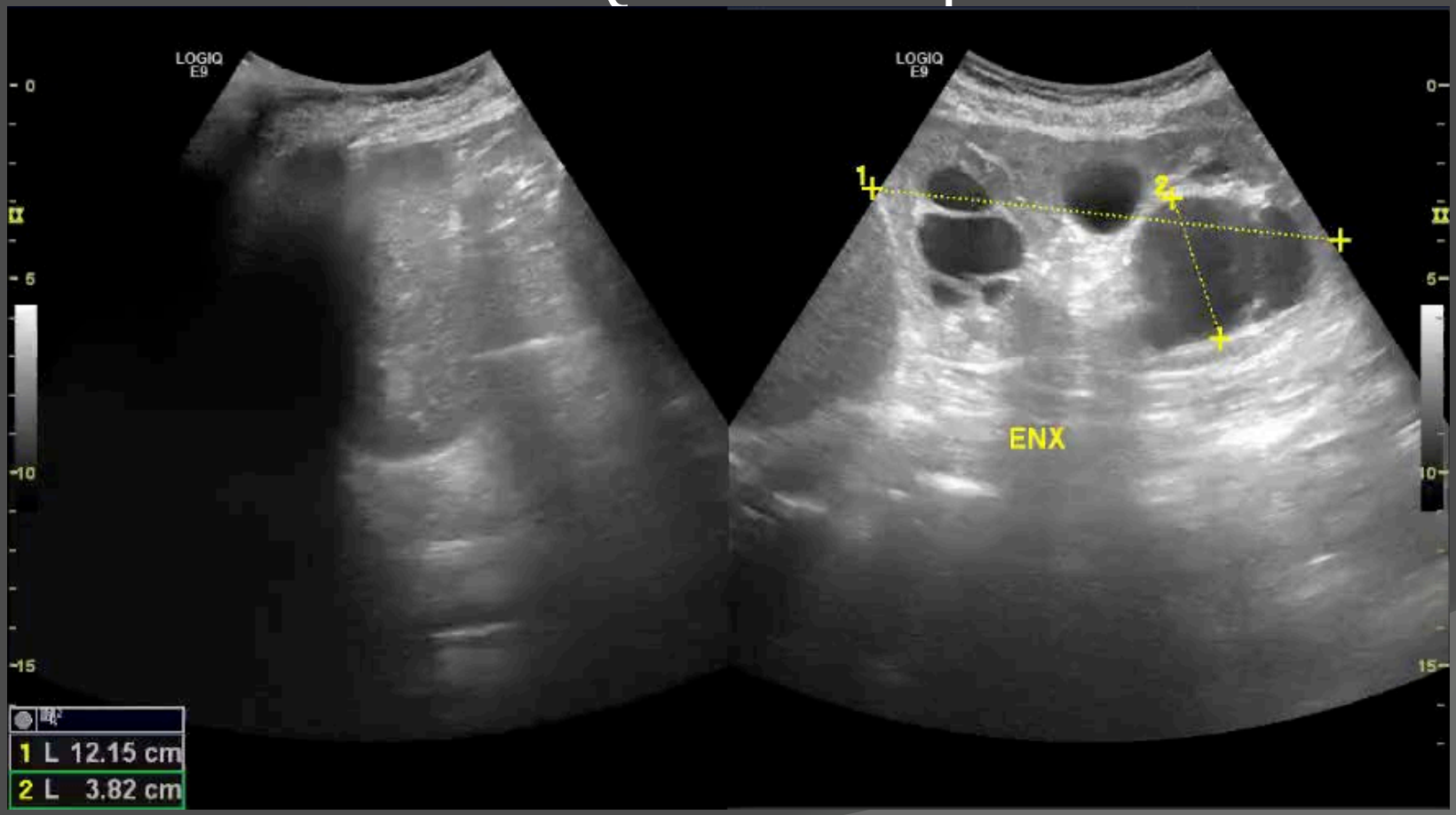

Rim

- Enxerto renal: Quisto complexo

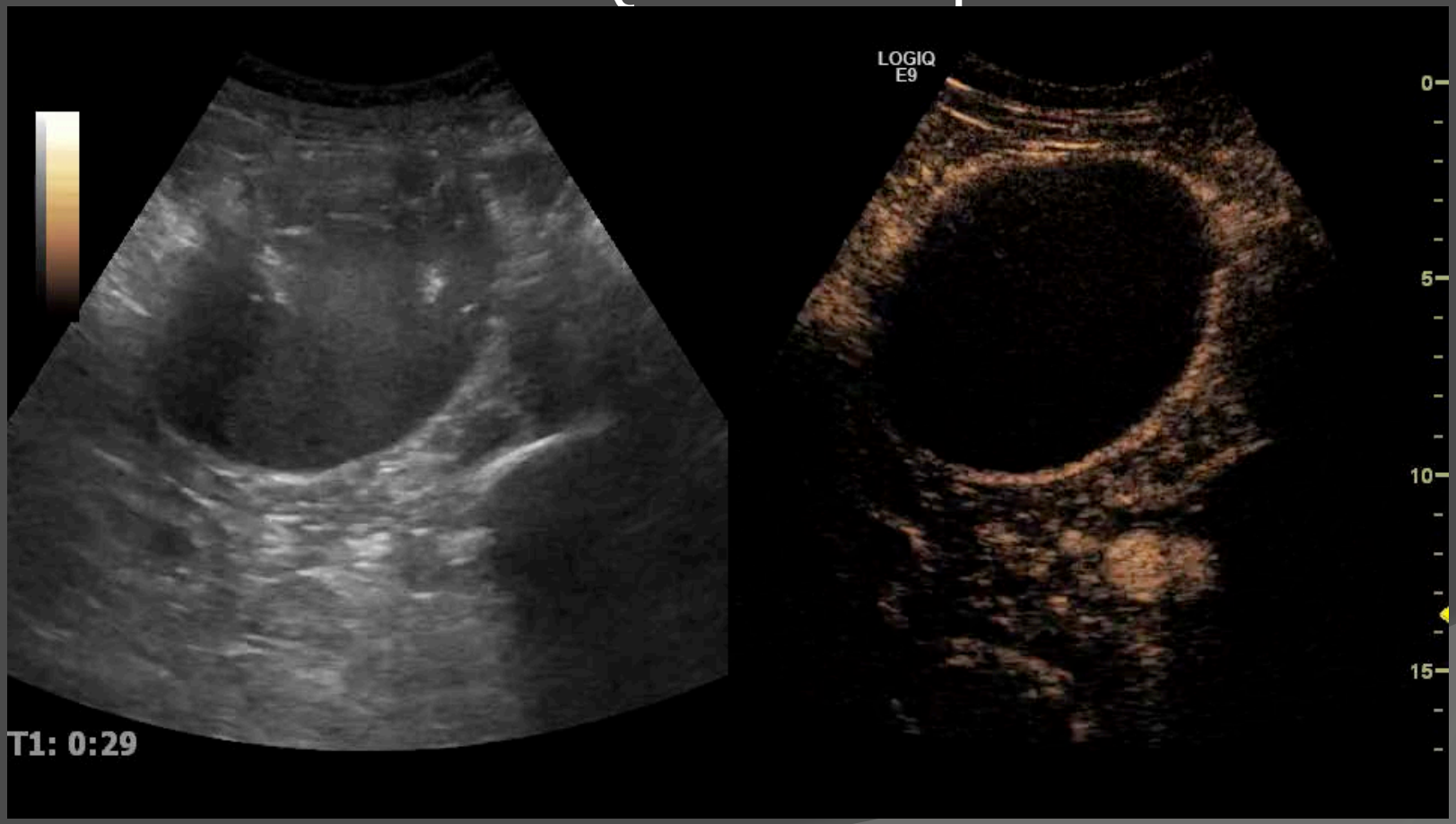

Rim

Outras aplicações:

- Tumor vs pseudotumor
- Lesões sólidas benignas vs malignas
- Termoablação
- Enfarte
- Hematoma

Tracto gastrointestinal

- DII

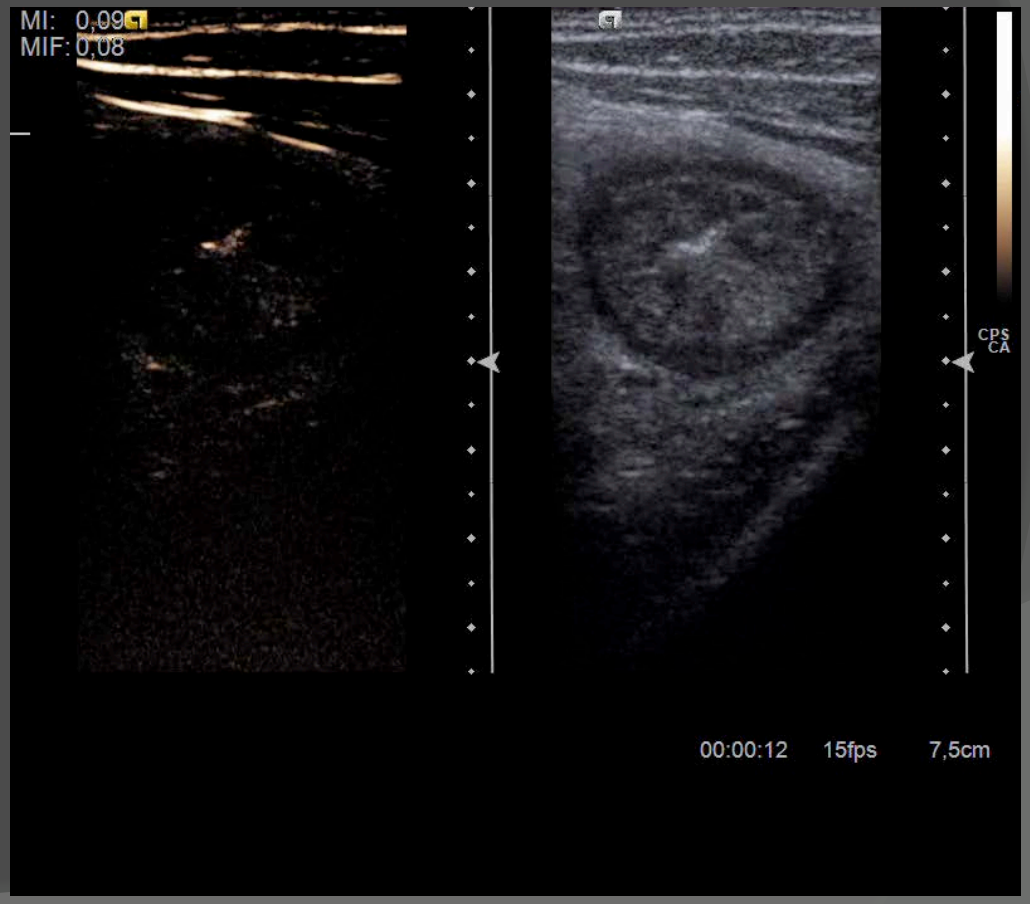

Tracto gastrointestinal

- DII

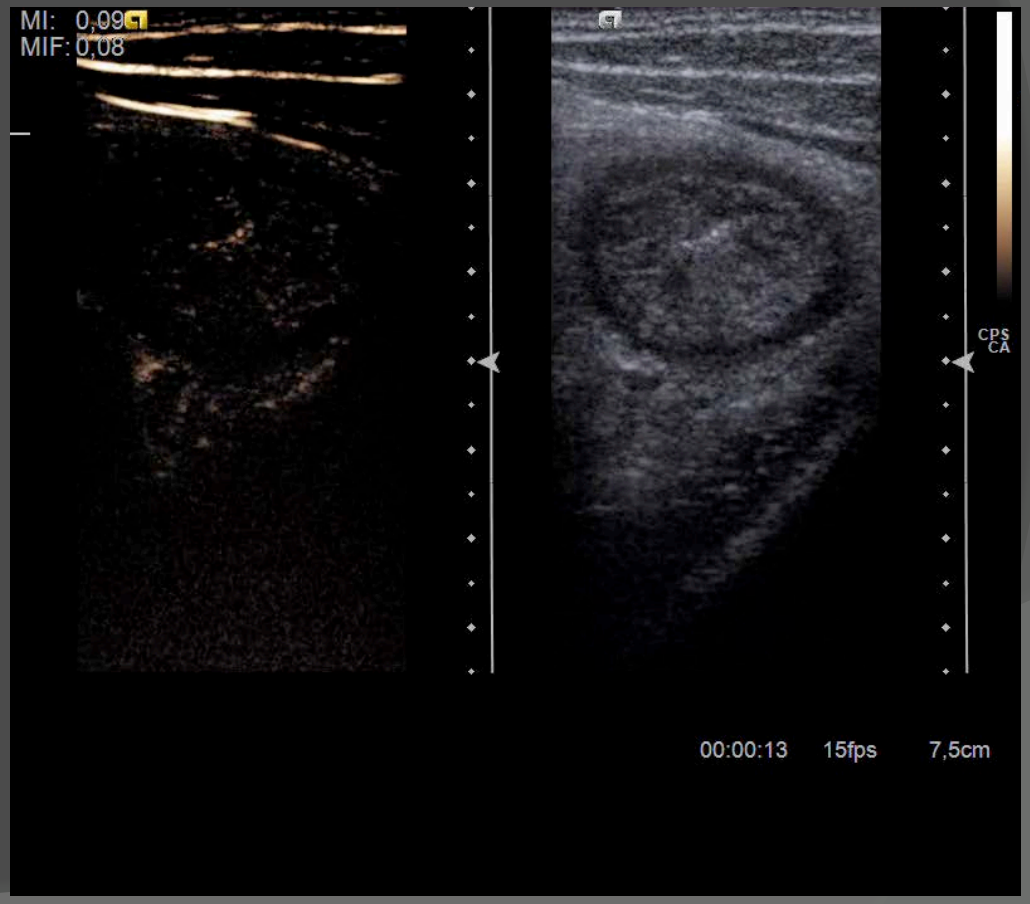

Tracto gastrointestinal

- DII

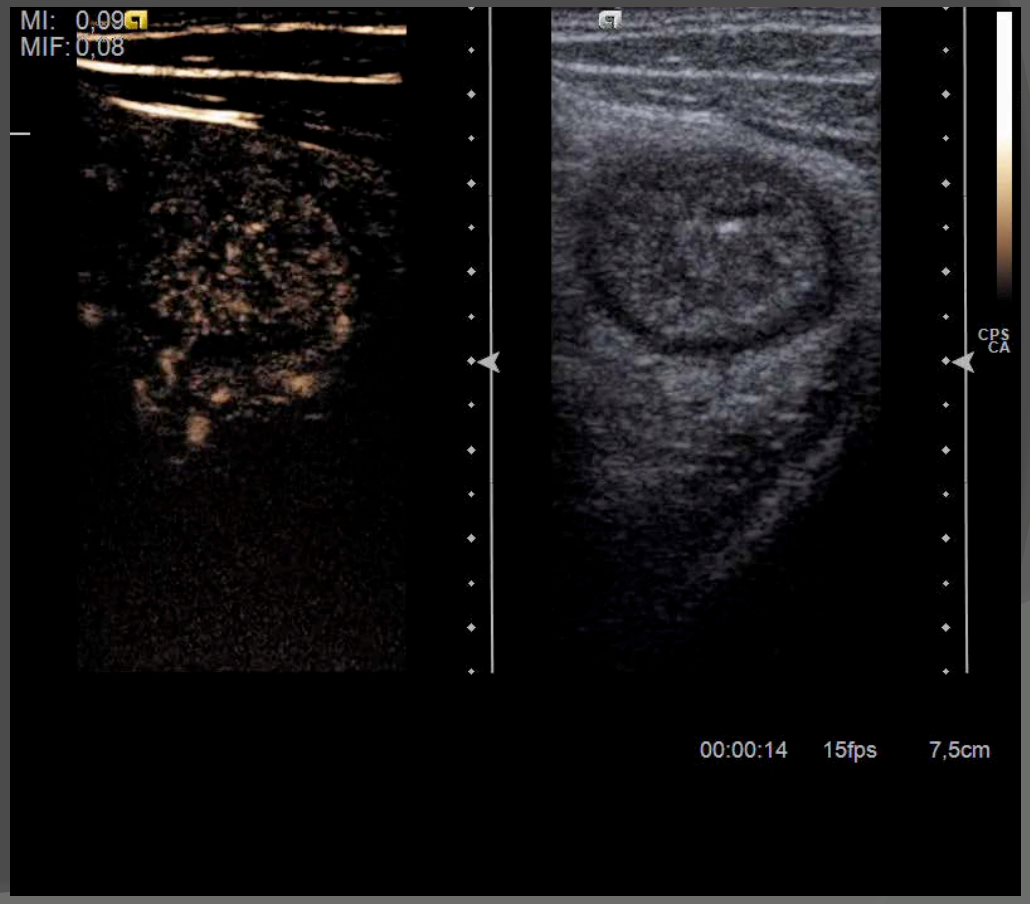

Tracto gastrointestinal

- DII

Tracto gastrointestinal

- DII

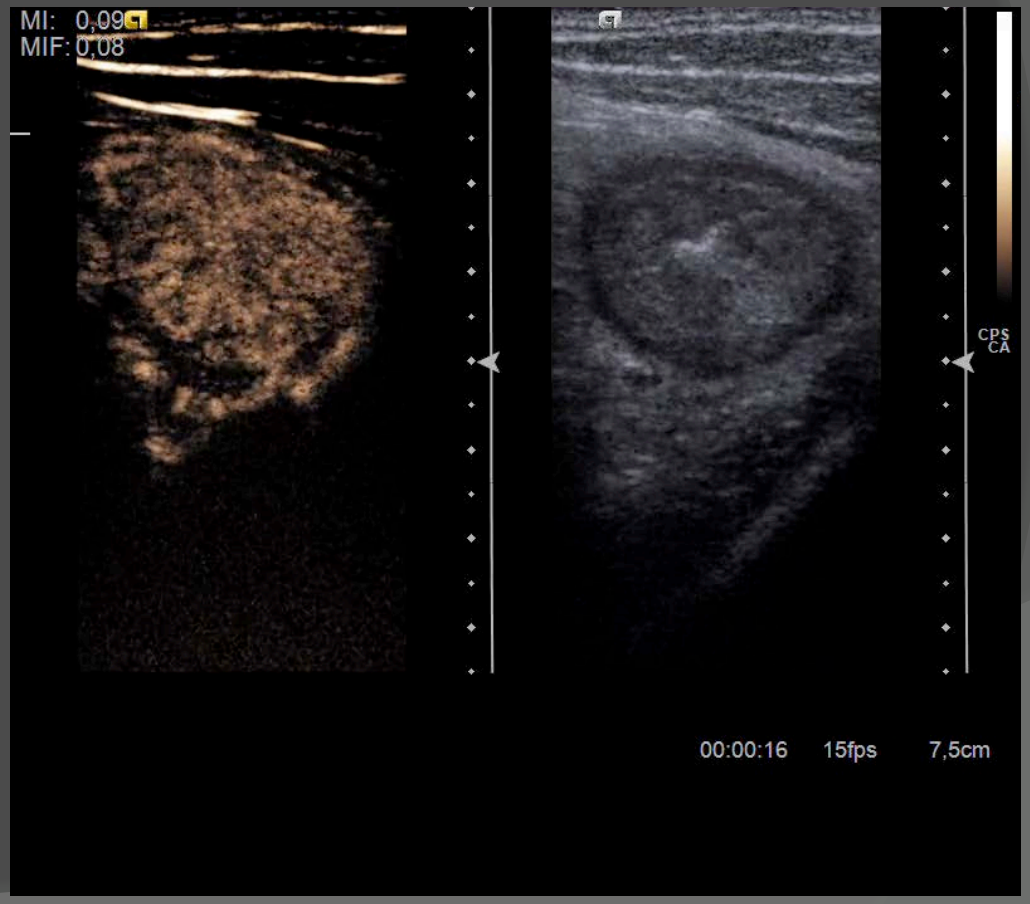

Tracto gastrointestinal

- DII

Tracto gastrointestinal

DII

- Actividade
- Monitorização terapêutica
- Estenose fibrosa vs inflamatória
- Abcesso
- “Fistulografia”

Vascular

- Aneurisma da aorta abdominal

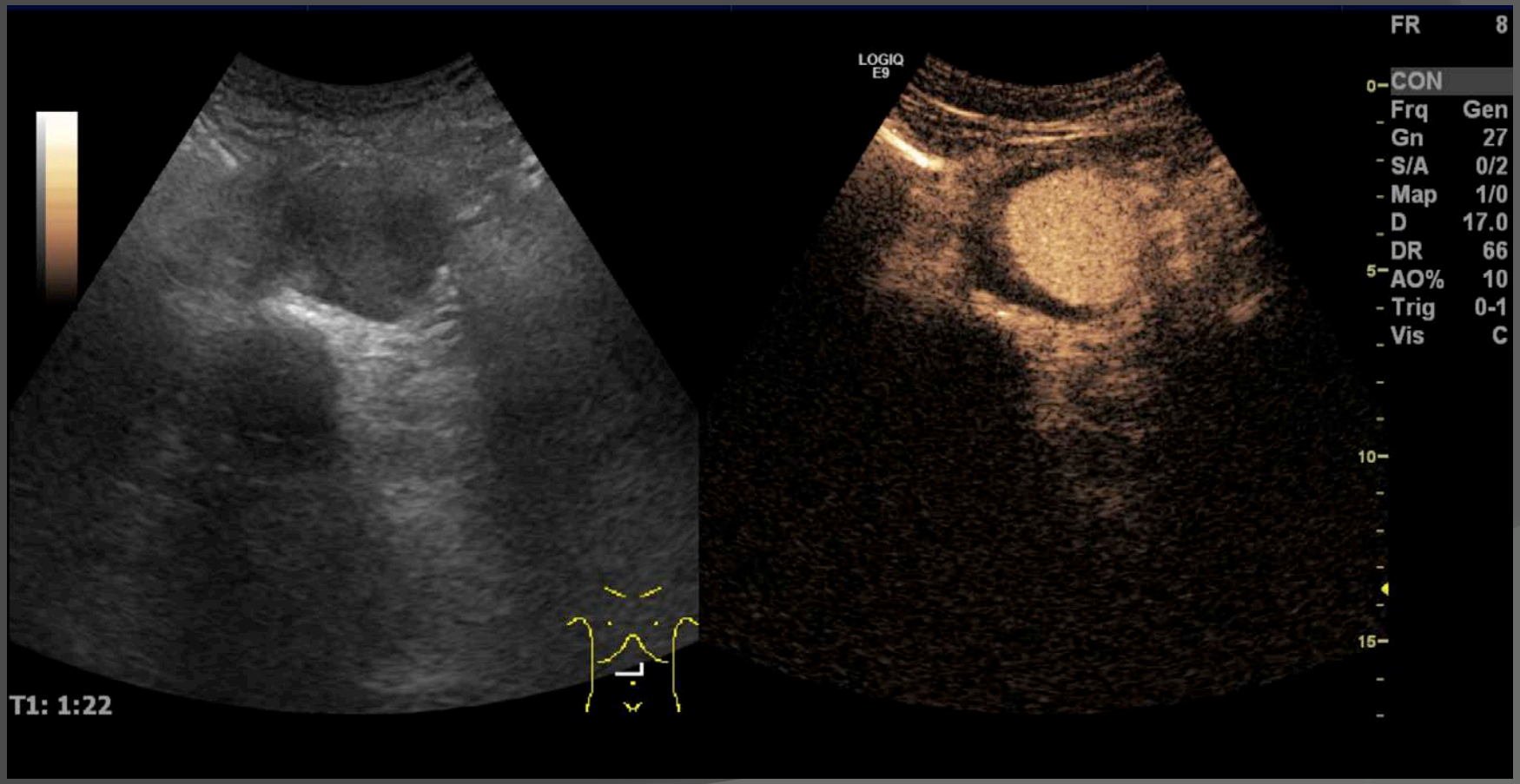

Vascular

- Aneurisma da aorta abdominal

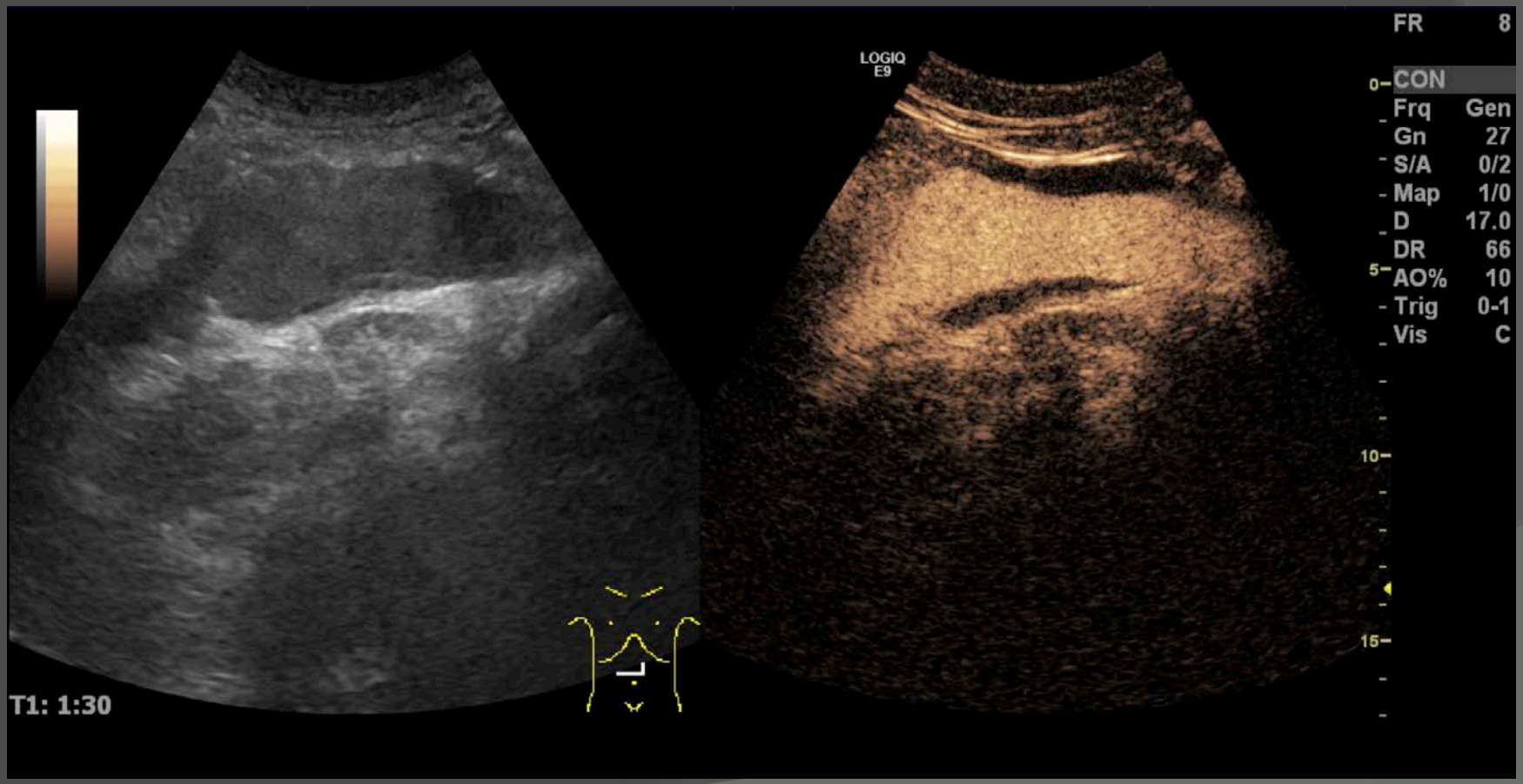

Vascular

Outras aplicações na aorta:

- Seguimento de prótese (endofugas)

Vascular

Outras aplicações:

- Trombose da veia porta

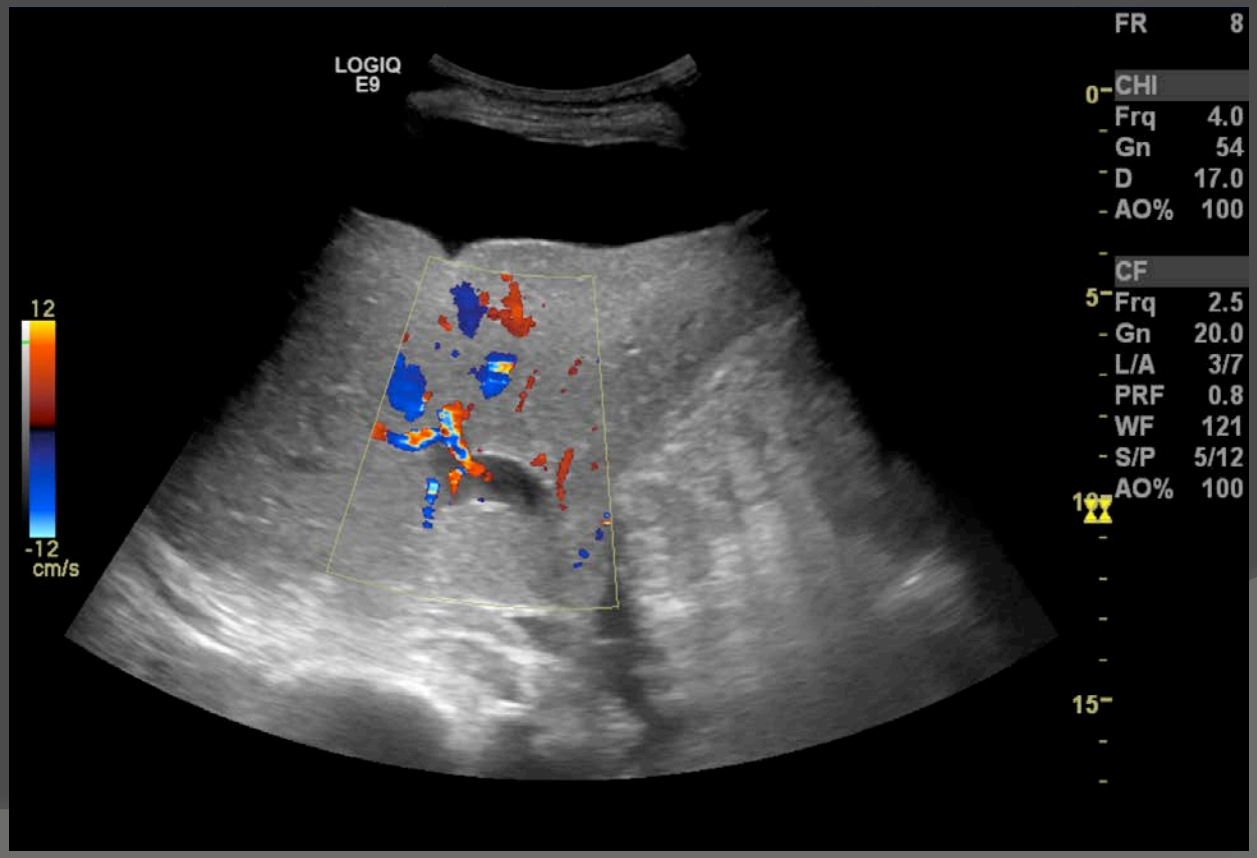

Vascular

Outras aplicações:

- Trombose da veia porta

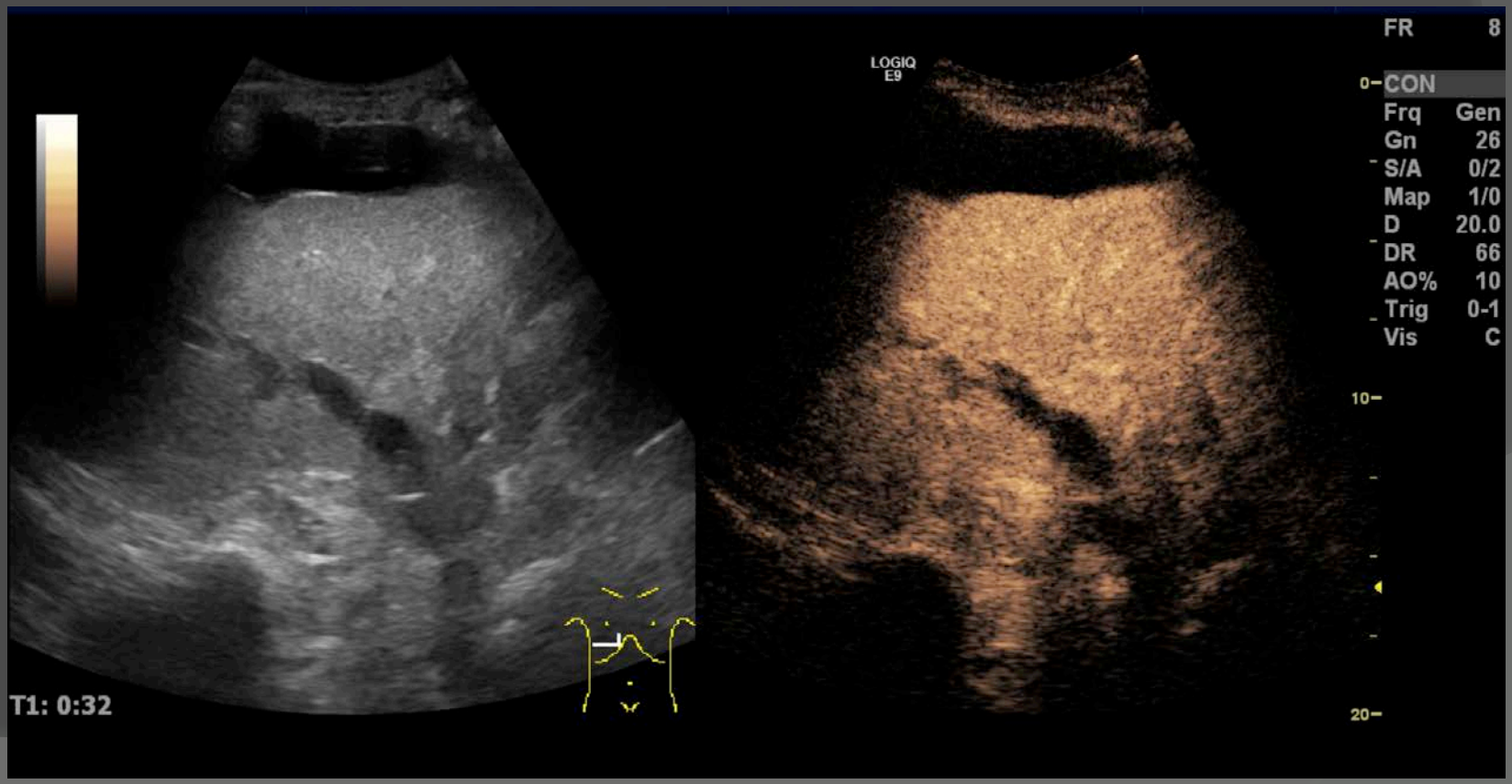

Conclusões

- Vantagens CEUS:
  - Ausência de nefrotoxicidade
  - Ausência de exposição radiação
  - Execução em tempo real

- Aplicada noutros órgãos que não o fígado

Bibliografia

- Caremani M, Occhini U, Caremani A, Tacconi D, Lapini L, Accorsi A, et al. Focal splenic lesions: US findings. J Ultrasound. 2013;16(2):65-74.
- Faccioli N, Crippa S, Bassi C, D'Onofrio M. Contrast-enhanced ultrasonography of the pancreas. Pancreatology. 2009;9(5):560-6.
- McArthur C, Baxter GM. Current and potential renal applications of contrast-enhanced ultrasound. Clin Radiol. 2012;67(9):909-22.
- Piscaglia F, Nolsøe C, Dietrich CF, Cosgrove DO, Gilja OH, Bachmann Nielsen M, et al. The EFSUMB Guidelines and Recommendations on the Clinical Practice of Contrast Enhanced Ultrasound (CEUS): update 2011 on non-hepatic applications. Ultraschall Med. 2012;33(1):33-59.
- Wilson SR, Greenbaum LD, Goldberg BB. Contrast-enhanced ultrasound: what is the evidence and what are the obstacles? AJR Am J Roentgenol. 2009;193(1):55-60.